

# Intraarterial Chemotherapy and Osmotic Blood-Brain Barrier Disruption for Patients With Embryonal and Germ Cell Tumors of the Central Nervous System

Kristoph Jahnke, MD<sup>1,2</sup>  
 Dale F. Kraemer, PhD<sup>3,4,5</sup>  
 Kristin R. Knight, MS<sup>6</sup>  
 David Fortin, MD<sup>7</sup>  
 Susan Bell, RN, MS, CNRN, CNP<sup>8</sup>  
 Nancy D. Doolittle, PhD<sup>1</sup>  
 Leslie L. Muldoon, PhD<sup>1,9</sup>  
 Edward A. Neuwelt, MD<sup>1,10,11</sup>

<sup>1</sup> Department of Neurology, Oregon Health & Science University, Portland, Oregon.

<sup>2</sup> Department of Medicine, Oregon Health & Science University, Portland, Oregon.

<sup>3</sup> Department of Medical Informatics and Clinical Epidemiology, Oregon Health & Science University, Portland, Oregon.

<sup>4</sup> Department of Public Health and Preventive Medicine, Oregon State University, Portland, Oregon.

<sup>5</sup> Department of Pharmacy Practice, Oregon State University, Portland, Oregon.

<sup>6</sup> Department of Pediatric Audiology, Oregon Health & Science University, Portland, Oregon.

<sup>7</sup> Centre Hospitalier Universitaire de Sherbrooke, Department of Neurosurgery and Neurooncology, Sherbrooke, Quebec, Canada.

<sup>8</sup> Department of Neurosurgery, The Ohio State University Medical Center, Columbus, Ohio.

<sup>9</sup> Department of Cell and Developmental Biology, Oregon Health & Science University, Portland, Oregon.

<sup>10</sup> Department of Neurosurgery, Oregon Health & Science University, Portland, Oregon.

<sup>11</sup> Veterans Affairs Medical Center, Portland, Oregon.

Supported by a Merit Review Grant from the Department of Veterans Affairs.

Grant sponsor: NIH; Grant numbers: NS33618, NS44687.

**BACKGROUND.** The rate of durable responses in embryonal and certain germ cell tumors of the central nervous system (CNS) is unsatisfactory. Intraarterial chemotherapy and osmotic blood-brain barrier disruption (IA/BBBD) increases drug delivery to the CNS.

**METHODS.** Data of patients treated with carboplatin or methotrexate-based IA/BBBD on prospective phase 2 trials conducted at 3 centers were collected. Study outcomes included overall survival (OS), time to progression (TTP), and toxicity.

**RESULTS.** Fifty-four patients were treated. Twenty-seven patients received IA/BBBD as salvage treatment. The median OS was 2.8 years for all patients, 2.5 years for supratentorial and disseminated primitive neuroectodermal tumors (PNETs,  $n = 29$ ), 1.7 years for medulloblastomas ( $n = 12$ ), and 5.4 years for germ cell tumors ( $n = 13$ ). OS and TTP for all patients were better with a Karnofsky Performance Status  $\geq 70\%$  ( $P = .0013$  and  $.0070$ ) and IA/BBBD as first-line treatment ( $P = .0059$  and  $.029$ ). In PNETs, OS was higher with pineal location ( $P = .045$ ) and IA/BBBD as first-line treatment ( $P = .0036$ ), and TTP was improved with radiotherapy before IA/BBBD ( $P = .036$ ) and IA/BBBD as first-line treatment ( $P = .0079$ ). Seventeen of 54 patients (31%) are alive, and 16 are alive at 4+ to 18+ years. Three survivors were not treated with radiotherapy and 4 were treated with focal radiotherapy only. The patients who were not irradiated did not develop dementia.

**CONCLUSIONS.** Survival and toxicity data appear promising, considering the cohort's adverse prognostic profile. A plateau in survival curves suggests a cure for some patients. Long-term survival may be achieved with focal or reduced-dose radiotherapy in some IA/BBBD patients. *Cancer* 2008;112:581-8. © 2007 American Cancer Society.

**KEYWORDS:** blood-brain barrier disruption, embryonal tumors, germ cell tumors.

**E**mbryonal tumors of the central nervous system (CNS) are the most common malignant brain neoplasms in children, but occur

Drs. Neuwelt and Muldoon, Oregon Health & Science University (OHSU), Portland Veterans Affairs Medical Center (PVAMC) and the Department of Veterans Affairs have a significant financial interest in Adherex, a company that may have a commercial interest in the results of this research and technology. This potential conflict of interest was reviewed and managed by the OHSU Integrity Program Oversight Council and the PVAMC Conflict of Interest in Research Committee. Dr. Neuwelt has divested his financial interests in Adherex.

We thank Kellie J. Nazemi, MD, for her expert assistance in reviewing this manuscript.

Address for reprints: Edward A. Neuwelt, Department of Neurology, Blood-Brain Barrier and Neuro-Oncology Program, Oregon Health and Science University, 3181 Sam Jackson Park Road, L603, Portland, OR 97239-3098; Fax: (503) 494-5627; E-mail: neuwelte@ohsu.edu

Received May 8, 2007; revision received July 31, 2007; accepted August 27, 2007.

less frequently in adults.<sup>1</sup> Of these, medulloblastomas are the most common type, accounting for 12%–25% of all CNS tumors in children, but for only 0.5%–1% of all intracranial neoplasms in adults.<sup>1,2</sup> Supratentorial primitive neuroectodermal tumors (sPNETs) comprise only 1%–2% of all childhood CNS tumors and are even less frequent in adults.<sup>3</sup> The mainstay of treatment for medulloblastomas and other embryonal brain tumors has been maximal surgical resection, craniospinal axis radiotherapy (CSA-RT) with focal boost, and multiagent chemotherapy. Since 1970 survival in medulloblastoma patients has markedly improved. Seventy percent, and in some reports up to 80%, of children with this disease can be cured, compared with approximately 50% 30 years ago.<sup>4,5</sup> However, many patients suffer neuropsychological sequelae and neurocognitive decline.<sup>6,7</sup> Furthermore, chemotherapy regimens are usually platinum-based, and platinum agents are associated with significant ototoxicity. This may contribute to developmental delay as well.<sup>8</sup> Embryonal tumors other than medulloblastoma still carry a very poor prognosis.<sup>3,9</sup>

Primary CNS germ cell tumors are rare, constituting less than 5% of all brain tumors.<sup>1</sup> Pure germinomas are extremely sensitive to both irradiation and platinum-based chemotherapy, and CSA-RT alone achieves a 5-year event-free survival of 91%.<sup>10</sup> In contrast, nongerminomatous germ cell tumors have an inferior prognosis when compared with pure germinomas.<sup>11</sup> The prognosis in germ cell tumors with dissemination or recurrence is dismal.<sup>12</sup>

The lack of durable responses in embryonal and germ cell tumors of the CNS treated with chemotherapy may, in part, be caused by the blood-brain barrier (BBB).<sup>13</sup> Intraarterial (IA) chemotherapy in conjunction with transient osmotic BBB disruption (IA/BBBD) has been shown to increase drug delivery to the CNS while preserving neurocognitive functioning and minimizing systemic toxicity.<sup>13,14</sup> Here we report the efficacy and toxicity of IA/BBBD in 54 patients with embryonal and germ cell CNS tumors, hypothesizing that long-term survival may be possible with IA/BBBD-enhanced chemotherapy delivery to the entire CNS and focal or reduced-dose radiotherapy.

## MATERIALS AND METHODS

### Study Design

Data were collected from patients with germ cell and embryonal CNS tumors prospectively treated with IA/BBBD on phase 2 study protocols from July 1981 to September 2006. Three centers affiliated with the

**TABLE 1**  
Chemotherapy Regimens Used With Number of Patients (n) Who Received the Respective Regimen

Protocol and chemotherapy agents	Doses
Protocol 1: methotrexate-cyclophosphamide-procarbazine 1981–1990; n = 7	
Methotrexate IA	2500 mg/d, Days 1+2
Cyclophosphamide IV	15 mg/kg/d, Days 1+2
Procarbazine PO	100 mg/d, Days 1–14
Protocol 2: carboplatin-etoposide(–cyclophosphamide) 1990–9/30/2006; n = 47	
Carboplatin IA	200 mg/m <sup>2</sup> /d, Days 1+2
Etoposide IV	200 mg/m <sup>2</sup> /d, Days 1+2
Cyclophosphamide IV	330 mg/m <sup>2</sup> /d, Days 1+2
Protocol 3: methotrexate-etoposide-cyclophosphamide 1993–9/30/2006; n = 4*	
Methotrexate IA	2500 mg/d, Days 1+2
Etoposide IV or IA	150 mg/m <sup>2</sup> /d, Days 1+2
Cyclophosphamide IV	500 mg/m <sup>2</sup> /d, Days 1+2

IA indicates intraarterially; IV, intravenously; PO, orally; d, day.

\* As first-line treatment, protocol 3 was used only for patients who did not tolerate the carboplatin-etoposide(–cyclophosphamide) regimen (eg, because of ototoxicity). Therefore, all 4 patients received protocol 2 first and were later switched to protocol 3.

BBBD Consortium participated. Data were extracted from password-protected institutional databases and verified using the patients' records. Original pathology reports, computed tomography (CT), and magnetic resonance imaging (MRI) scans were reviewed at participating centers to verify histopathologic diagnoses and radiographic tumor characteristics. Institutional Review Board approval for the release of anonymized data was obtained from each participating center.

### Treatment Protocols

All patients were treated on phase 2 protocols approved by the individual Institutional Review Board. An overview of all protocols is provided in Table 1. Data were prospectively collected at study entry and at every visit during the study. Eligibility criteria were similar in all protocols and included histologically/cytologically confirmed CNS germ cell or embryonal tumor; age at first treatment  $\leq 75$  years; life expectancy of  $\geq 90$  days; negative pregnancy test and adequate birth control methods in women with childbearing potential; normal renal, hepatic, and hematologic functions; no uncontrolled significant medical conditions; no radiographic signs of intracranial herniation and/or spinal cord block; no second malignancy; and signed written informed consent. Prior radiation or chemotherapy was allowed. Patients with significant mass effect at the time of protocol enrollment were given IA chemotherapy without BBBD before starting IA/BBBD.

The IA/BBBD technique and the concomitant supportive care have been described in detail elsewhere.<sup>14,15</sup> Briefly, BBBD treatment was done on 2 consecutive days every 4 weeks for up to 1 year, for a maximum of 24 treatments per patient. Under general anesthesia a femoral artery was accessed, and either an internal carotid or vertebral artery was catheterized up to the level of approximately C2 in the internal carotid and C7 in the vertebral artery. In the case of multifocal disease, both internal carotid arteries and 1 vertebral artery were catheterized in an alternating fashion to ensure homogeneous drug delivery throughout the affected brain regions. Warmed (37°C) 25% mannitol was delivered at a predetermined flow rate of 3–12 mL/s into the intracranial artery for 30 seconds. After administration of mannitol, the IA chemotherapy agent (carboplatin or methotrexate) was infused over 10 minutes. Intravenous chemotherapy (cyclophosphamide and/or etoposide [phosphate]) was begun directly after induction of general anesthesia.

As reported previously, corticosteroids were routinely used with disruption of the vertebral artery after administration of carboplatin.<sup>15</sup> Assessment of tumor response was based on CT and/or MRI scans obtained every 4 weeks before each treatment and interpreted using the Macdonald criteria.<sup>16</sup> Toxicity was monitored according to the National Cancer Institute Common Toxicity Criteria. All patients were monitored weekly with complete blood counts. A biochemical liver and kidney function profile and electrolyte assessment was done every 4 weeks. Follow-up examinations were performed according to a standardized schedule and included physical examinations, CT, and/or MRI scans, cerebrospinal fluid (CSF) studies, and ophthalmologic evaluations.

Some patients in this study received intravenous sodium thiosulfate (STS). A phase 1 clinical study of STS protection against carboplatin-induced high-frequency hearing loss started in 1996.<sup>17</sup> STS was initially given over 15 minutes, 2 hours after carboplatin. Patients received 1 or 2 doses of STS, depending on baseline hearing status. High-dose STS (16 or 20 g/m<sup>2</sup>) was found to be safe and effective against carboplatin-induced hearing loss.<sup>18</sup> In 1998, STS was delayed to 4 hours postcarboplatin, based on new information suggesting a greater time of increased BBB permeability than previously assumed.

Patients were removed from the IA/BBBD protocol upon disease progression, unacceptable toxicity, or according to a patient's or physician's decision.

### Statistical Considerations

Study endpoints included overall survival (OS) and time to progression (TTP), each from the date of first

study treatment, and toxicity. Times to events were censored using a data cutoff date (September 30, 2006) and estimated using the Kaplan-Meier product limit method. Categorical variables that could represent possible prognostic factors for TTP and OS (age, sex, Karnofsky Performance Status [KPS], chemotherapy or radiotherapy before IA/BBBD, radiotherapy at any time during treatment, recurring or refractory disease before study entry, pineoblastoma/atypical pineocytoma histology) were evaluated with the generalized Wilcoxon test for all patients and the supratentorial/disseminated PNET subgroup. The significance level was .05 (2-sided) for all statistical tests.

## RESULTS

### All Patients

A summary of all 54 patients is provided in Tables 1 (IA/BBBD treatment data) and 2 (patient characteristics). Diagnosis was established by stereotactic biopsy in 11 (20%) and resection in 42 (78%) patients. One patient was initially diagnosed with CT/MRI only and biopsied at recurrence. Chemotherapy regimens before IA/BBBD study entry were platinum-based in 17 (31%) patients.

A total of 789 IA/BBBD treatments were administered. Fifty-two patients were treated with combination chemotherapy in conjunction with sequential osmotic BBBD 24 hours apart via the internal or vertebral arteries. Two patients were treated with IA chemotherapy only (without BBBD). Nine (17%) patients could not be assessed for response because they had no measurable disease at the time of enrollment into the IA/BBBD protocol. TTP and OS for all patients were 1.2 (95% confidence interval, 0.7–1.8) and 2.8 (1.7–5.4) years, respectively. Twelve (22%) patients are progression-free. Forty percent of patients survived  $\geq 4.2$  years, and 30% survived  $\geq 8.7$  years (Fig. 1). OS and TTP were significantly better in patients with a KPS  $\geq 70\%$  ( $P = .0013$  and  $.0070$ ) and in those with IA/BBBD as first-line treatment ( $P = .0059$  and  $.029$ ).

Treatment-related toxicities are summarized in Table 3. No treatment-related deaths and no permanent neurologic or vascular sequelae from the IA/BBBD procedure were observed. All 4 patients who developed dementia and all 3 who died from delayed neurotoxicity (age range, 1–53 years) received CSA-RT. Patients treated after 1996 on a carboplatin-based protocol were given delayed intravenous STS. However, the dose of STS and timing of STS delivery varied, depending on the date the patient entered the study. Thus, patients in this study received heterogeneous STS regimens, and an accurate analysis of the effect of STS on hearing protection was not feasible.

**TABLE 2**  
Patient Characteristics, Organized by Histologic Subgroups

Variable	All patients (n = 54)	Supratentorial and disseminated PNETs (n = 29)	Medulloblastomas (n = 12)	Germ cell tumors	
				All patients (n = 13)	Pure germinomas only (n = 10)
<b>Descriptive data</b>					
Median age (range), y	22.4 (1.2–53.5)	20.5 (1.2–53.5)	27 (8–46)	23 (11–35)	20.5 (12–28)
Median KPS (range), %	80 (15–100)	90 (35–100)	80 (50–100)	80 (15–100)	82.5 (50–100)
No. of patients (%) with available data					
Female gender	25 (46)	16 (55)	5 (42)	4 (31)	3 (30)
Disseminated disease	13 (24)	5 (17)	0	8 (62)	7 (70)
Positive CSF cytology	6/45 (13)	3/25 (12)	1/9 (11)	2/11 (18)	2/9 (22)
<b>Treatment Data</b>					
Chemotherapy alone before IA/BBBD	11 (20)	5 (17)	0	6 (46)	6 (60)
Radiotherapy alone before IA/BBBD	7 (13)	4 (14)	3 (25)	0	0
Chemotherapy+radiotherapy prior to IA/BBBD	11 (20)	4 (14)	5 (42)	2 (15)	1 (10)
IA/BBBD as salvage treatment*	22 (41)	11 (38)	8 (67)	3 (23)	2 (20)
Dexamethasone during IA/BBBD	29 (54)	17 (59)	7 (58)	5 (38)	3 (30)
IA/BBBD chemotherapy dose reduction	20 (38)	12 (43)	3 (25)	5 (38)	5 (50)
Best response to IA/BBBD					
Complete remission	14/45 (31)	6/26 (23)	4/11 (36)	4/8 (50)	3/5 (60)
Partial remission	18/45 (40)	11/26 (42)	5/11 (45)	2/8 (25)	2/5 (40)
Stable disease	9/45 (20)	7/26 (27)	1/11 (9)	1/8 (12)	0
Progressive disease	4/45 (9)	2/26 (8)	1/11 (9)	1/8 (12)	0
Consolidation radiotherapy after IA/BBBD					
First relapse	42 (78)	20 (69)	12 (100)	10 (77)	7 (70)
Chemotherapy alone					
Chemotherapy alone	16/41 (39)	5/19 (26)	8 (67)	3 (30)	2 (29)
Chemotherapy+radiotherapy	7/41 (17)	5/19 (26)	1 (8)	1 (10)	1 (14)
Chemotherapy+radiotherapy	9/41 (22)	4/19 (21)	2 (17)	3 (30)	3 (43)
Alive					
Alive	17 (31)	9 (31)	2 (17)	6 (46)	6 (60)
Cause of death					
Tumor progression	32 (86)	16 (80)	10 (100)	6 (86)	3 (75)
Neurotoxicity <sup>†</sup>	3 (8)	2 (10)	0	1 (14)	1 (25)
Other toxicity/other causes	2 (5)	2 (10)	0	0	0

PNETs indicates primitive neuroectodermal tumors; n, number of patients; KPS, Karnofsky performance status; CSF, cerebrospinal fluid; IA/BBBD, intraarterial chemotherapy and blood-brain barrier disruption.

\* Ie, patients have either failed or did not respond completely to prior treatment.

<sup>†</sup> All patients received cranial radiation over the course of their disease.

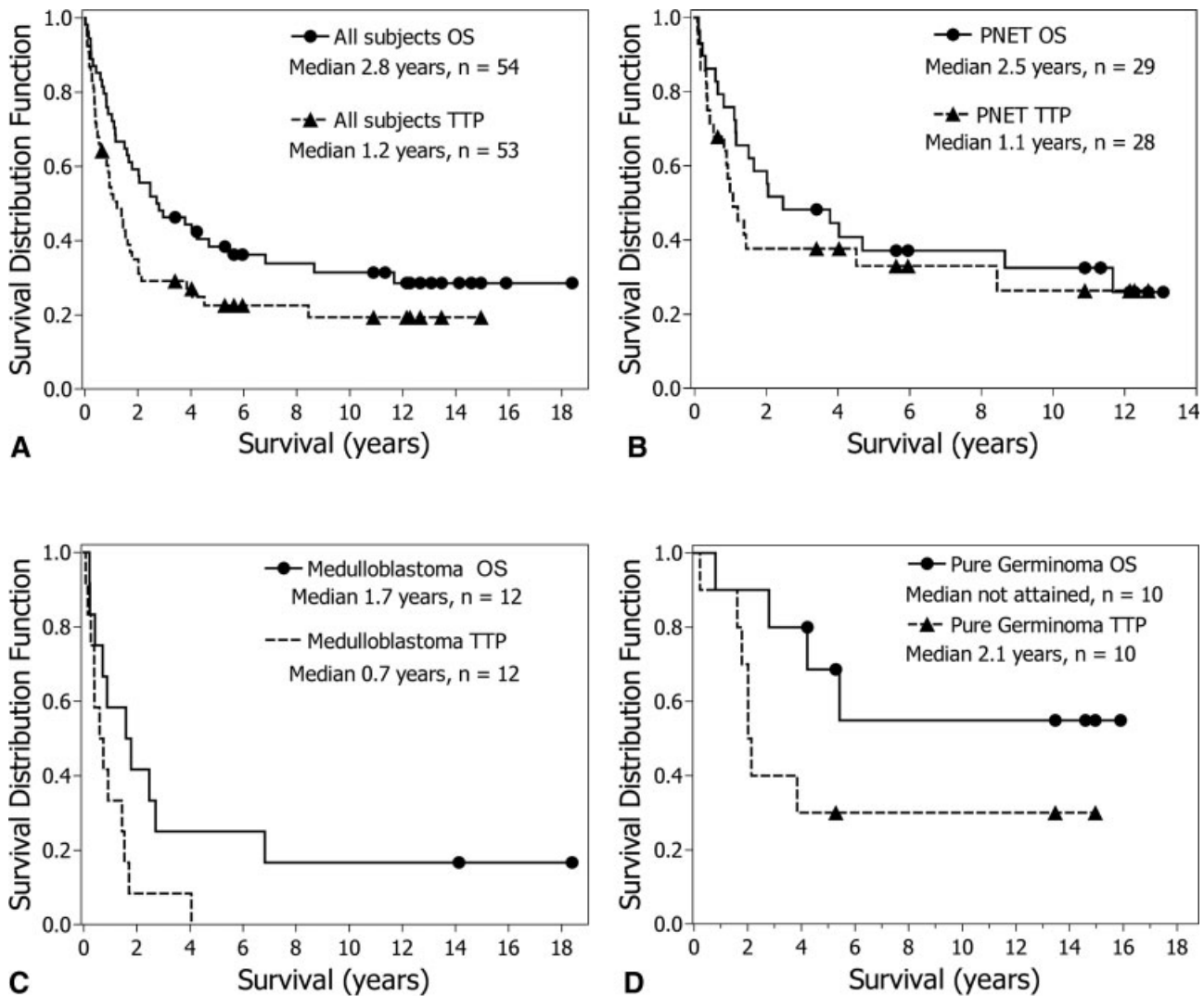
Patients were grouped into 4 distinct histologic classes based on the current World Health Organization (WHO) classification<sup>1</sup> and their distinct clinical prognosis: supratentorial and disseminated PNET (n = 29; 46%), medulloblastoma (n = 12; 19%), and germ cell tumor (n = 13 patients; 21%). Patient characteristics, organized by histologic classes, are presented as follows and in Table 2.

#### Supratentorial and disseminated PNETs

Twenty-nine patients were identified in this subgroup. Pathologic diagnoses included pineoblastoma (n = 13), atypical pineocytoma (n = 2), neuroblastoma (n = 3), and other supratentorial or disseminated PNETs (n = 11). Eleven patients (38%) received IA/BBBD as salvage treatment. Median TTP was 1.1 (0.8–8.4) years, and 9 (31%) patients are pro-

gression-free. Thirty percent of patients had no progression at 4.5 years. Four (14%) patients had no progression at 11+ years postinitiation of treatment. Median OS was 2.5 (1.2–11.7) years. Forty percent survived 4 years and 30% survived 8.7 years (Fig. 1). OS was significantly better with pineal location ( $P = .045$ ) and IA/BBBD as first-line treatment ( $P = .0036$ ), and TTP was significantly improved with radiotherapy before IA/BBBD ( $P = .036$ ) and IA/BBBD as first-line treatment ( $P = .0079$ ). Nine (31%) patients are alive in complete remission, and 6 (21%) are alive 11+ years after first treatment. Seven of 9 (78%) patients who are alive are without progression after IA/BBBD treatment. All 9 survivors received radiation, including adjuvant radiotherapy after IA/BBBD (n = 7), radiation at recurrence (n = 1), and radiotherapy both before IA/BBBD and at recurrence





**FIGURE 1.** Kaplan-Meier estimates of TTP and OS for all study patients (Top left,  $n = 63$ ), supratentorial and disseminated PNETs (Top right,  $n = 29$ ), medulloblastomas (Bottom left,  $n = 12$ ), and pure germinomas (Bottom right,  $n = 10$ ).

( $n = 1$ ). Four survivors were treated with focal radiotherapy only (3 adjuvantly and 1 at recurrence).

#### Medulloblastomas

In this subgroup with 12 patients, IA/BBBD was administered as salvage treatment in 8 (67%) patients. Three patients survived 6.8 years (Fig. 1). Median TTP was 0.7 (0.4–1.4) years, and all 12 patients have progressed. Median OS was 1.7 (0.7–2.7) years. Two patients are still alive in complete remission at 14+ and 18+ years, and both received CSA-RT at recurrence.

#### Germ cell tumors

Thirteen patients, including 10 with pure germinomas and 3 with nongerminomatous germ cell tumors,

were identified. Eight (62%) patients had disseminated disease at the time of study entry. Three patients in this group received IA/BBBD as salvage treatment. Median TTP was 2.0 (0.5–3.9) years, and 3 patients (all with pure germinomas) are without progression. Two patients have not progressed 13+ years after first treatment. Median OS was 5.4 years (2.8 years to not reached). Median TTP for the pure germinoma patients was 2.1 (1.8 to not reached) years, and median OS was not attained in this group. TTP of the 3 patients with nongerminomatous germ cell tumors was 0.025, 0.36, and 0.48 years, and OS was 0.027, 1.02, and 2.95 years. Of the 6 (46%) patients who are still alive, all are in complete remission, and 4 (31%) have survived 13+ years (Fig. 1). All survivors had pure germinomas, 5 had disseminated disease, and 1

**TABLE 3**  
**Summary of Toxicities Observed With 789 IA/BBBD Treatments in 54 Patients**

Toxicity	No. of events (patients)	Incidence (% of procedures)
<b>Neurological</b>		
Reversible neurologic deficit (Duration >24 to 48 h)	17 (12)	2.2
Asymptomatic extracranial arterial injury	2 (2)	0.3
Reversible cervical spinal cord toxicity	1 (1)	0.1
Status epilepticus	1 (1)	0.1
<b>Nonneurological</b>		
Transfusions of platelets*	(19)	2.4
Transfusions of packed red blood cells*	(18)	2.3
Neutropenic fever	18 (13)	2.3
Septicemia (non-neutropenic)	5 (3)	0.6
Deep venous thrombosis	3 (3)	0.4
Pulmonary embolism	2 (2)	0.3
Pneumonia	1 (1)	0.1
Dysrhythmia	2 (2)	0.3
Femoral artery injury	1 (1)	0.1
Femoral arterial thrombosis	1 (1)	0.1
<b>Late complications</b>		
Orthopedic (fractures, avascular necrosis)	3 (3)	0.4
Ophthalmological <sup>†</sup>	4 (4)	0.5
Dementia <sup>‡</sup>	4 (4)	0.5
Acute myelogenous leukemia	1 (1)	0.1

IA/BBBD indicates intraarterial chemotherapy and blood-brain barrier disruption; CSA-RT, craniospinal axis radiotherapy.

\* Number of units transfused could not be retrieved.

<sup>†</sup> Includes >50% decrease in visual acuity and asymptomatic macular degeneration (2 cases each).

<sup>‡</sup> All patients CSA-RT over the course of their disease.

had recurring disease at the start of IA/BBBD. Three of the 6 (50%) survivors are without progression after IA/BBBD and have not received radiotherapy, and the other 3 were treated with CSA-RT (n = 2) and whole-brain radiation (n = 1) at recurrence.

## DISCUSSION

### IA Chemotherapy and BBBD

The role of standard chemotherapy in the treatment of brain tumors has been limited, presumably because the BBB prevents passage of ionized water-soluble substances with a molecular weight >180 Da.<sup>13</sup> IA chemotherapy into selected cerebral vessels significantly increases the intratumoral chemotherapy concentration in animal studies.<sup>13</sup> Adding transient osmotic BBBD to the IA chemotherapy infusion can improve delivery of the chemotherapeutic agents outside the center of the tumor.<sup>13</sup> A correlation of dose intensity and survival was demonstrated in CNS lymphoma patients treated with IA/BBBD,<sup>19</sup> and none of the assessed patients suffered neurocognitive decline.<sup>14</sup>

The safety of IA/BBBD, including the preservation of neurocognitive function, has been reported previously.<sup>14,20</sup> Our results further support these reports.

### Supratentorial and Disseminated PNETs, Medulloblastomas

Medulloblastomas and PNETs are classified as either average/standard risk or high risk according to certain prognostic factors. The latter group includes patients with disease dissemination and all sPNETs.<sup>21,22</sup> Patients with pineal region sPNETs had a better outcome than patients with nonpineal sPNETs in this study, a finding consistent with the literature.<sup>23,24</sup> The nonexistence of a survival benefit in patients with a high KPS also confirms previous findings.

Medulloblastoma/PNET is generally treated by maximal surgical resection followed by CSA-RT and adjuvant chemotherapy.<sup>4,21,25</sup> In contrast to average-risk medulloblastoma, sPNETs, high-risk medulloblastomas, and recurring patients still carry a poor prognosis. The latter may contribute to the significantly lower OS and TTP in our patients who did not receive IA/BBBD as first-line treatment. According to current published data, children with sPNETs have an overall 5-year survival rate of about 34%.<sup>3,9</sup>

Medulloblastoma and PNET nearly always require cranial radiation, but many patients suffer neuropsychological sequelae and neurocognitive decline.<sup>6,7</sup> The question whether radiation fields and doses can be reduced by using chemotherapy is therefore of high importance. In a pilot study with 16 medulloblastoma/sPNET patients treated with IA/BBBD chemotherapy (among them 7 [44%] with disseminated disease), the response rate of 69% compared favorably to 10 previously published series using conventional treatment.<sup>26</sup> High-dose chemotherapy with stem cell support may also be beneficial in PNET and medulloblastoma patients, albeit at the cost of significant acute toxicity.<sup>27-30</sup> Conventional multiagent chemotherapy was able to cure children with early-stage, completely resected newly diagnosed medulloblastoma, but was insufficient for treatment of metastatic or incompletely resected tumors.<sup>31</sup>

Many patients in our study had adverse prognostic factors. For example, 38% of the sPNET/disseminated PNET and 67% of the medulloblastoma patients received IA/BBBD as salvage treatment. Considering the presence of these adverse prognostic factors, our survival data for PNET seem promising, and the long follow-up of this study with a plateau in survival suggests that select patients with this diagnosis may be cured. Interestingly, the 2 long-term survivors in the medulloblastoma group were spared

radiation upfront and received CSA-RT with focal boost at recurrence. It should be noted that all survivors in the PNET/medulloblastoma group received radiation, and patients in the PNET group who received radiotherapy before IA/BBBD had a significantly higher TTP. This underscores the importance of radiation in this disease. However, because of the observation that long-term survival and even cure may be possible with dose-intense IA/BBBD chemotherapy and adjuvant or even salvage radiation, this approach should be investigated further, including studies with reduced radiation fields and doses. This suggestion is supported by the finding that 4 long-term survivors in the PNET group received focal radiation only, thus sparing them the possible side effects of standard CSA-RT.

This study has several limitations. The pathologic classification of our PNET/medulloblastoma patients in this study must be regarded with caution because the current WHO classification for embryonal CNS tumors<sup>1</sup> has changed frequently in the past because of advances in diagnostics. Furthermore, like in many other published studies, the sample size in our study is small, and comparison to the existing literature is difficult due to the heterogeneity of the patient collectives.

### Germ Cell Tumors

Patients with disseminated germ cell tumors, recurring disease, or nongerminomatous histology have an unfavorable prognosis.<sup>11,12</sup> Strategies that used conventional intravenous chemotherapy alone were effective in achieving remission in germ cell tumors, but long-term outcome has been unsatisfactory.<sup>32,33</sup> These disappointing results, coupled with the significant neurotoxicity associated with cranial radiotherapy, have led to the pursuit of alternative therapy approaches focusing on chemotherapy. In 9 patients with disseminated or hypothalamic germ cell tumors treated with IA/BBBD chemotherapy, 6 were alive 19 to 60 months after diagnosis.<sup>26</sup> Of these, 4 remained in complete remission. In another study using high-dose chemotherapy and autologous stem cell rescue the overall results were promising. However, only 4 of 12 (33%) nongerminomatous germ cell tumor patients survived without evidence of disease, with a median survival of 35 months.<sup>34</sup>

The 13 patients included in our study had an adverse prognostic profile. Eight (62%) had disseminated disease, 3 had nongerminomatous histology, and 3 received IA/BBBD as salvage treatment. Nevertheless, 6 of 8 (75%) assessable patients responded to IA/BBBD. Furthermore, 5 patients without evidence of disease at the time of study entry (3 of whom had

disseminated disease at diagnosis) were still in complete remission after treatment. The median OS of 5.4 years for all patients appears promising. Not surprisingly and, in accordance with the literature,<sup>11,12</sup> survival in pure germinomas was better than in nongerminomatous tumors. All 6 survivors had pure germinomas. However, 5 had disseminated disease and 1 had recurring disease at start of IA/BBBD, indicating an unfavorable prognosis. Of the 6 patients alive in complete remission, none has received radiotherapy upfront or adjuvantly, and all patients either remained in or achieved a complete response after IA/BBBD. Although the number of patients is small, our data suggest that in patients with pure germinomas treated with IA/BBBD, radiotherapy could possibly be deferred until recurrence, and certain patients may even be cured by IA/BBBD alone, sparing them the side effects associated with radiation.

### Conclusion

The response, survival, and toxicity data appear promising, especially when considering that many patients carried adverse prognostic factors. A plateau in survival curves in conjunction with the long median follow-up in this study suggests possible cure for some patients with sPNETs and germinomas. Long-term survival is possible with IA/BBBD-enhanced chemotherapy delivery to the entire CNS and focal or reduced-dose radiotherapy in some of these patients. Future studies are needed to confirm these results.

### REFERENCES

1. Kleihues P, Cavenee WK (eds.). World Health Organization Classification of Tumours. Pathology and Genetics of Tumours of the Nervous System. Lyon: IARC; 2000.
2. Sarkar C, Deb P, Sharma MC. Recent advances in embryonal tumours of the central nervous system. *Childs Nerv Syst.* 2005;21:272–293.
3. Rorke LB, Hart MN, McLendon RE. Supratentorial primitive neuroectodermal tumour. In: Kleihues P, Cavenee WK, eds. World Health Organization Classification of Tumours. Pathology and Genetics of Tumours of the Nervous System. Lyon: IARC; 2000:141–144.
4. Packer RJ. Progress and challenges in childhood brain tumors. *J Neurooncol.* 2005;75:239–242.
5. Packer RJ, Gajjar A, Vezina G, et al. Phase III study of craniospinal radiation therapy followed by adjuvant chemotherapy for newly diagnosed average-risk medulloblastoma. *J Clin Oncol.* 2006;24:4202–4208.
6. Hoppe-Hirsch E, Renier D, Lellouch-Tubiana A, Sainte-Rose C, Pierre-Kahn A, Hirsch JF. Medulloblastoma in childhood: progressive intellectual deterioration. *Childs Nerv Syst.* 1990;6:60–65.
7. Walter AW, Mulhern RK, Gajjar A, et al. Survival and neurodevelopmental outcome of young children with medulloblastoma at St Jude Children's Research Hospital. *J Clin Oncol.* 1999;17:3720–3728.

8. Ilveskoski I, Saarinen UM, Wiklund T, et al. Ototoxicity in children with malignant brain tumors treated with the "8 in 1" chemotherapy protocol. *Med Pediatr Oncol.* 1998;27:26–31.
9. Ironside JW, Moss TH, Louis DN, Lowe JS, Weller RO. Embryonal tumours. In: Ironside JW, Moss TH, Louis DN, Lowe JS, Weller RO, eds. *Diagnostic Pathology of Nervous System Tumours.* London: Churchill Livingstone; 2002:185–215.
10. Bamberg M, Kortmann RD, Calaminus G, et al. Radiation therapy for intracranial germinoma: results of the German cooperative prospective trials MAKEI 83/86/89. *J Clin Oncol.* 1999;17:2585–2592.
11. Calaminus G, Andreussi L, Garre ML, Kortmann RD, Schober R, Gobel U. Secreting germ cell tumors of the central nervous system (CNS). First results of the cooperative German/Italian pilot study (CNS sGCT). *Klin Padiatr.* 1997;209:222–227.
12. Allen JC, Kim JH, Packer RJ. Neoadjuvant chemotherapy for newly diagnosed germ-cell tumors of the central nervous system. *J Neurosurg.* 1987;67:65–70.
13. Neuwelt EA. Mechanisms of disease: the blood-brain barrier. *Neurosurgery.* 2004;54:131–140.
14. McAllister LD, Doolittle ND, Guastadisegni PE, et al. Cognitive outcomes and long-term follow-up results after enhanced chemotherapy delivery for primary central nervous system lymphoma. *Neurosurgery.* 2000;46:51–60.
15. Doolittle ND, Murillo TP, Neuwelt EA. Blood-brain barrier disruption chemotherapy. In: Newton HB, ed. *Handbook of Brain Tumor Chemotherapy.* London: Elsevier; 2006:262–273.
16. Macdonald DR, Cascino TL, Schold SC Jr, Cairncross JG. Response criteria for phase II studies of supratentorial malignant glioma. *J Clin Oncol.* 1990;8:1277–1280.
17. Neuwelt EA, Brummett RE, Doolittle ND, et al. First evidence of otoprotection against carboplatin-induced hearing loss with a 2-compartment system in patients with central nervous system malignancy using sodium thiosulfate. *J Pharmacol Exp Ther.* 1998;286:77–84.
18. Doolittle ND, Muldoon LL, Brummett RE, et al. Delayed sodium thiosulfate as an otoprotectant against carboplatin-induced hearing loss in patients with malignant brain tumors. *Clin Cancer Res.* 2001;7:493–500.
19. Kraemer DE, Fortin D, Doolittle ND, Neuwelt EA. Association of total dose intensity of chemotherapy in primary central nervous system lymphoma (human non-acquired immunodeficiency syndrome) and survival. *Neurosurgery.* 2001;48:1033–1040.
20. Doolittle ND, Miner ME, Hall WA, et al. Safety and efficacy of a multicenter study using intraarterial chemotherapy in conjunction with osmotic opening of the blood-brain barrier for the treatment of patients with malignant brain tumors. *Cancer.* 2000;88:637–647.
21. Zeltzer PM, Boyett JM, Finlay JL, et al. Metastasis stage, adjuvant treatment, and residual tumor are prognostic factors for medulloblastoma in children: conclusions from the Children's Cancer Group 921 randomized phase III study. *J Clin Oncol.* 1999;17:832–845.
22. Reddy AT, Janss AJ, Phillips PC, Weiss HL, Packer RJ. Outcome for children with supratentorial primitive neuroectodermal tumors treated with surgery, radiation, and chemotherapy. *Cancer.* 2000;88:2189–2193.
23. Cohen BH, Zeltzer PM, Boyett JM, et al. Prognostic factors and treatment results for supratentorial primitive neuroectodermal tumors in children using radiation and chemotherapy: a Childrens Cancer Group randomized trial. *J Clin Oncol.* 1995;13:1687–1696.
24. Timmermann B, Kortmann RD, Kuhl J, et al. Role of radiotherapy in the treatment of supratentorial primitive neuroectodermal tumors in childhood: results of the prospective German brain tumor trials HIT 88/89 and 91. *J Clin Oncol.* 2002;20:842–849.
25. Packer RJ, Sutton LN, Elterman R, et al. Outcome for children with medulloblastoma treated with radiation and cisplatin, CCNU, and vincristine chemotherapy. *J Neurosurg.* 1994;81:690–698.
26. Dahlborg SA, Petrillo A, Crossen JR, et al. The potential for complete and durable response in nongliar primary brain tumors in children and young adults with enhanced chemotherapy delivery. *Cancer J Sci Am.* 1998;4:110–124.
27. Strother D, Ashley D, Kellie SJ, et al. Feasibility of 4 consecutive high-dose chemotherapy cycles with stem-cell rescue for patients with newly diagnosed medulloblastoma or supratentorial primitive neuroectodermal tumor after craniospinal radiotherapy: results of a collaborative study. *J Clin Oncol.* 2001;19:2696–2704.
28. Chi SN, Gardner SL, Levy AS, et al. Feasibility and response to induction chemotherapy intensified with high-dose methotrexate for young children with newly diagnosed high-risk disseminated medulloblastoma. *J Clin Oncol.* 2004;22:4881–4887. [Erratum: *J Clin Oncol.*23:2877, 2005.]
29. Sung KW, Yoo KH, Cho EJ, et al. High-dose chemotherapy and autologous stem cell rescue in children with newly diagnosed high-risk or relapsed medulloblastoma or supratentorial primitive neuroectodermal tumor. *Pediatr Blood Cancer.* 2007;48:408–415.
30. Perez-Martinez A, Lassaletta A, Gonzalez-Vicent M, Sevilla J, Diaz MA, Madero L. High-dose chemotherapy with autologous stem cell rescue for children with high risk and recurrent medulloblastoma and supratentorial primitive neuroectodermal tumors. *J Neurooncol.* 2005;71:33–38.
31. Grill J, Sainte-Rose C, Jouvett A, et al. French Society of Paediatric Oncology. Treatment of medulloblastoma with postoperative chemotherapy alone: an SFOP prospective trial in young children. *Lancet Oncol.* 2005;6:573–580.
32. Balmaceda C, Heller G, Rosenblum M, et al. Chemotherapy without irradiation—a novel approach for newly diagnosed CNS germ cell tumors: results of an international cooperative trial—the First International Central Nervous System Germ Cell Tumor Study. *J Clin Oncol.* 1996;14:2908–2915.
33. Kellie SJ, Boyce H, Dunkel IJ, et al. Primary chemotherapy for intracranial nongerminomatous germ cell tumors: results of the second international CNS germ cell study group protocol. *J Clin Oncol.* 2004;22:846–853.
34. Modak S, Gardner S, Dunkel IJ, et al. Thiotepe-based high-dose chemotherapy with autologous stem-cell rescue in patients with recurrent or progressive CNS germ cell tumors. *J Clin Oncol.* 2004;22:1934–1943.